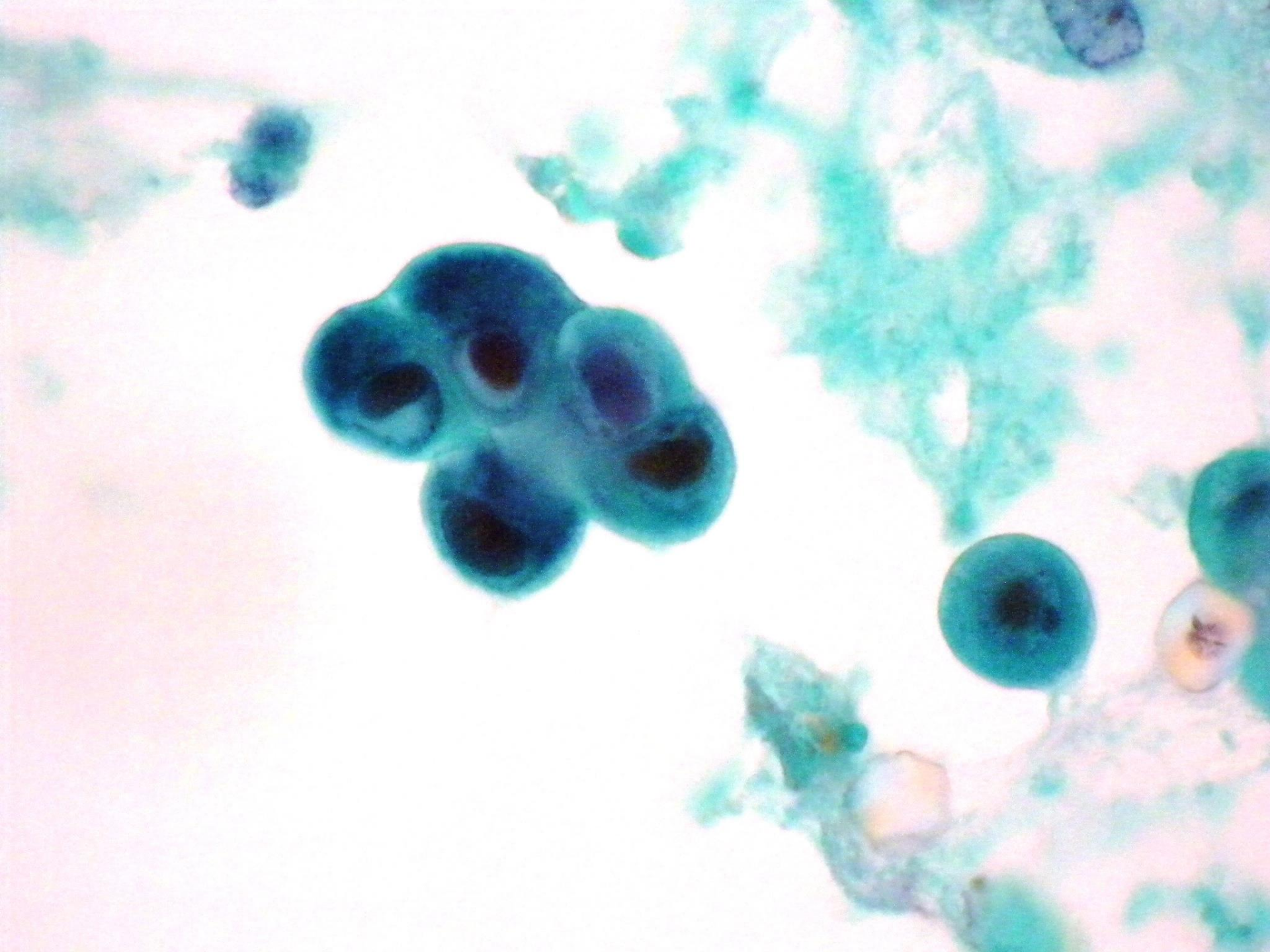
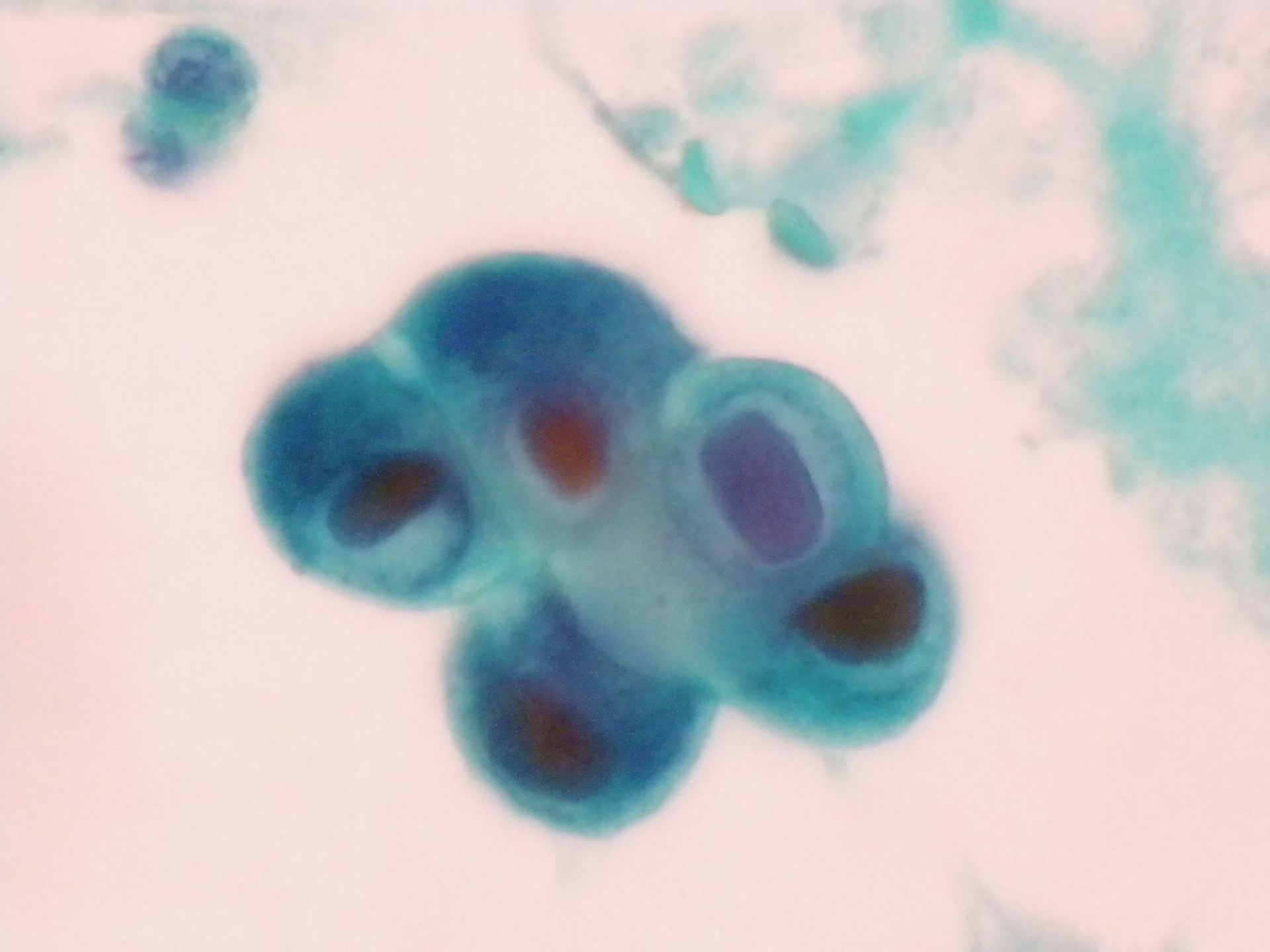


每月一例 2019 March

- 75 y/o, male
- Bronchoalveolar lavage
- Figure 1-2







Your interpretation ?



Cytology result

Negative for malignant cells

Consistent with CMV

